

---

# Clinical Outcomes of Wide Postsurgical Lesions in the Infected Diabetic Foot Managed With 2 Different Local Treatment Regimes Compared Using a Quasi-Experimental Study Design: A Preliminary Communication

Chiara Goretti, Sabrina Mazzurco, Laura Ambrosini Nobili, Silvia Macchiarini, Anna Tedeschi, Francesca Palumbo, Alessia Scatena, Loredana Rizzo, Alberto Piaggese  
Diabetic Foot Section, Department of Endocrinology and Metabolism, University of Pisa, Italy

---

*The safety and efficacy of a novel superoxidized solution (Dermacyn™ Wound Care [DWC], Oculus Innovative Sciences, Petaluma, Calif) was evaluated for the treatment of wide postsurgical infected ulcers of the diabetic foot. A group (group A, n = 18) of patients with diabetes mellitus who had postsurgical lesions >5 cm<sup>2</sup> without ischemia or infection were recruited consecutively and treated with DWC-saturated dressings. These dressings were renewed once daily and were compared with a group of patients that had been previously treated with diluted povidone iodine (group B, n = 15) using a quasi-experimental study design. Both sets of patients also received standard systemic antibiotic therapy, as per the practice in this center, and local surgical debridement. Patients had weekly assessments until wounds had re-epithelialized completely. Patients in group A had statistically significant*

*shorter healing time and duration of antibiotic therapy and a higher healing rate at 6 months compared with those in group B (p < .01). Recurrence of infection, requirement for debridement procedures, and requirement for minor amputations were significantly less frequent during follow-up in group A patients (p < .05) when compared with those in group B. These preliminary data suggest that DWC used as a wound dressing together with other local and systemic therapies may have a role in reducing healing time as well as complications in patients with diabetes who have postsurgical lesions of the diabetic foot. These data propose the need for a robust controlled study of DWC-saturated dressings to explore its full potential.*

**Key words:** superoxidized solution, diabetic foot ulcers, povidone iodine, antimicrobials, antiseptics

---

**C**linical management of the diabetic foot is complex with many different management therapeutic options, all of which have to be considered<sup>1,2</sup> in coming to a decision. Offloading, revascularization, and

control of infection are essential in the acute phases of the disease and have to be addressed to avoid therapeutic failures and recurrences.<sup>3</sup> The management of acute infected lesions of the diabetic foot is probably the most complex clinical problem in this pathology. Infections in the diabetic foot are serious because they may evolve, rapidly involving deep structures such as tendons, joints, and bones putting the patient's foot at risk of amputation and even putting the patient at risk for death. The situation is further complicated by the presence of peripheral arterial disease.<sup>1-3</sup> Guidelines for the treatment and management of the diabetic foot, outlined in the international consensus document on

---

Correspondence should be sent to: Alberto Piaggese, MD, Sezione Piede Diabetico, U.O. Malattie Metaboliche e Diabetologia, Azienda Ospedaliera Universitaria Pisana, Via Paradisa 2 – 56124, Pisa, Italy; phone/fax: +39050995114; e-mailpiaggese@immr.med.unipi.it.

Conflict of interest: None.

DOI: 10.1177/1534734606298543

© 2007 Sage Publications

the diabetic foot, recommend systemic and local treatments with the aim of encouraging wound healing and avoiding complications.<sup>4</sup>

Drainage and aggressive surgical debridement, combined with adequate systemic antibiotic treatment, are the cornerstones of therapy, especially in cases involving deep structures, which frequently lead to wide open lesions that can have difficulty in healing.<sup>5,6</sup>


In these circumstances, the use of local antiseptic solutions is controversial with no robust evidence to support the efficacy to achieve wound sterilization. There is clinical evidence that such solutions are widely used to reduce local bacterial load and to prevent further infection during the follow-up of wide postdrainage lesions, which may last for several months.<sup>7-9</sup> Dermacyn™ Wound Care (DWC, Oculus Innovative Sciences, Petaluma, Calif) is a novel superoxidized solution (SOS) made from the electrolysis of water and sodium chloride to generate reactive species of chlorine and oxygen. It is pH neutral. This solution has previously been used as an antibacterial agent for surgical hardware and has been proposed for use as an antiseptic in various conditions including chronic wounds. Studies have shown that the solution is non-toxic, and it is reported to accelerate wound healing in the rat model.<sup>10-12</sup>

In this article, a study of the safety and efficacy of DWC compared with standard treatment in the management of wide postdrainage lesions of the infected diabetic foot is reported using a quasi-experimental (nonrandomized) study design.

## MATERIALS AND METHODS

All patients with diabetes mellitus who underwent surgical debridement or drainage to treat diabetic foot infection in our department to treat diabetic foot infection between June and December 2004 were consecutively screened for entry into the study. The inclusion criteria were as follows: diabetes mellitus type 1 or type 2 according to the international guidelines for the diagnosis of diabetes<sup>13</sup>; a postsurgical lesion wider than 5 cm<sup>2</sup> graded 3B according to the Texas University grading scale; a lesion involving deep structures such tendons, joints, and bones<sup>14</sup>; transcutaneous oxygen tension (TcPO<sub>2</sub>) > 50 mm Hg distal to the ankle; and the presence of infection as documented by local and systemic signs with confirmation by positive microbiological investigations.

Patients were excluded in cases of bilateral ulceration, active or previous Charcot's foot, peripheral arterial disease not amenable to revascularization, or a life expectancy less than 1 year.



*Fig. 1* Equipment used for daily irrigation of the lesions with Dermacyn. A catheter, gauze, and a syringe. All items were sterile and disposable.

Patients who underwent lower limb revascularization, either surgical or endovascular, were admitted only if TcPO<sub>2</sub> measured at the dorsum of the foot after the procedure was >50 mm Hg.

The study protocol received the approval of the ethical committee of our hospital. Prior informed consent was obtained from participating patients. Foot lesions were measured using a tracing with polyurethane film and were subsequently photographed. This was followed by surgical debridement up to healthy viable tissue. The dressing of lesions was a sterile gauze soaked with DWC, which was renewed daily via a catheter to keep the gauze saturated with the solution (Figure 1). The foot was then bandaged. Patients were instructed to off-load the foot either by bed rest or by using a wheelchair when required. The inner gauze of the dressing was changed every 3 days until the patient was discharged. After the patient was discharged, the inner gauze was changed at weekly intervals at the foot clinic and the dressings were kept in place with post-operative shoes, which were wrapped in self-adherent bandages.<sup>15</sup> Patients and their relatives were given instructions on how to replace the DWC in the dressing to keep it saturated.

Patients received antibiotic therapy, which was discontinued if the results from 2 consecutive microbiological screens were negative and there were improvements in local and systemic signs of infection such as edema, erythema, increased temperature, discharge, tenderness, fever, or leukocytosis.

Concomitant medication was recorded throughout the study during the inpatient phase of the study

**Table 1.** Patient Demographics

	Group A	Group B	P
Number (DM1/DM2)	18 (4/14)	15 (3/12)	n.s.
Age – yrs	62.4 ± 9.7 (58.1-67.5)	63.7 ± 12.2 (58.2-68.9)	n.s.
Duration of Diabetes – yrs	21.7 ± 10.3 (17.1-26.4)	19.8 ± 9.1 (14.4-25.2)	n.s.
HbA1c – %	8.2 ± 1.1 (7.8-8.6)	8.8 ± 1.9 (8.4-9.2)	n.s.
Area of the lesion – cm <sup>2</sup>	25.8 ± 10.4 (19.7-31.8)	20.2 ± 12.3 (15.3-25.7)	n.s.
Duration of ulceration – days	95.7 ± 52.4 (68.3-116.3)	78.3 ± 65.8 (63.9-92.2)	n.s.

n.s. = not significant.

and at the weekly outpatient clinic visits. At each outpatient visit to the clinic, foot lesions were measured and photographed and any recurrence of infection was recorded.

In addition, adverse events were recorded and when necessary new local debridement was done. The necessity and the extent of debridement for each patient were evaluated during the study by the same diabetologist who had proven experience in the management of foot ulceration. Lesions were assessed according to the following variables: presence of necrosis, purulent secretion, fistulae, abscesses, fluctuation, and bone fragmentation cellulitis. These patients were classified under group A.

Patients were followed up to complete healing of the wound, which was considered as complete re-epithelialization for closure by secondary intent or with skin grafting. In the case of skin grafting, healing time was recorded at the moment of desaturation if the wound had completely closed. For wound closure by secondary intent, healing time was recorded after complete re-epithelialization had occurred.

The primary endpoints of the study were healing time, number of adverse events, and the proportion of patients whose wounds had healed at 6 months. Duration of antibiotic therapy, the number of recurrent or new infections, and the number of eventual new surgical procedures were the secondary endpoints.

We compared patients in group A with another group of patients (group B) who had previously received the standard treatment of 50% povidone iodine diluted with saline (group B) within the previous 12 months in our department in this center.

**DATA ANALYSIS**

Results were expressed as mean ± standard deviation (95% confidence intervals CI) and were analyzed using ANOVA for healing times, chi-square test for the proportion of patients healed at 6

months, the incidence of reinfection, the incidence of surgical debridement procedures, and the incidence of minor amputations and Mann-Whitney test for the duration of antibiotic therapy. All analyses were done using commercial software (Statview®, SAS Institute, URAY, NC). Statistical significance was set at the 5% level.

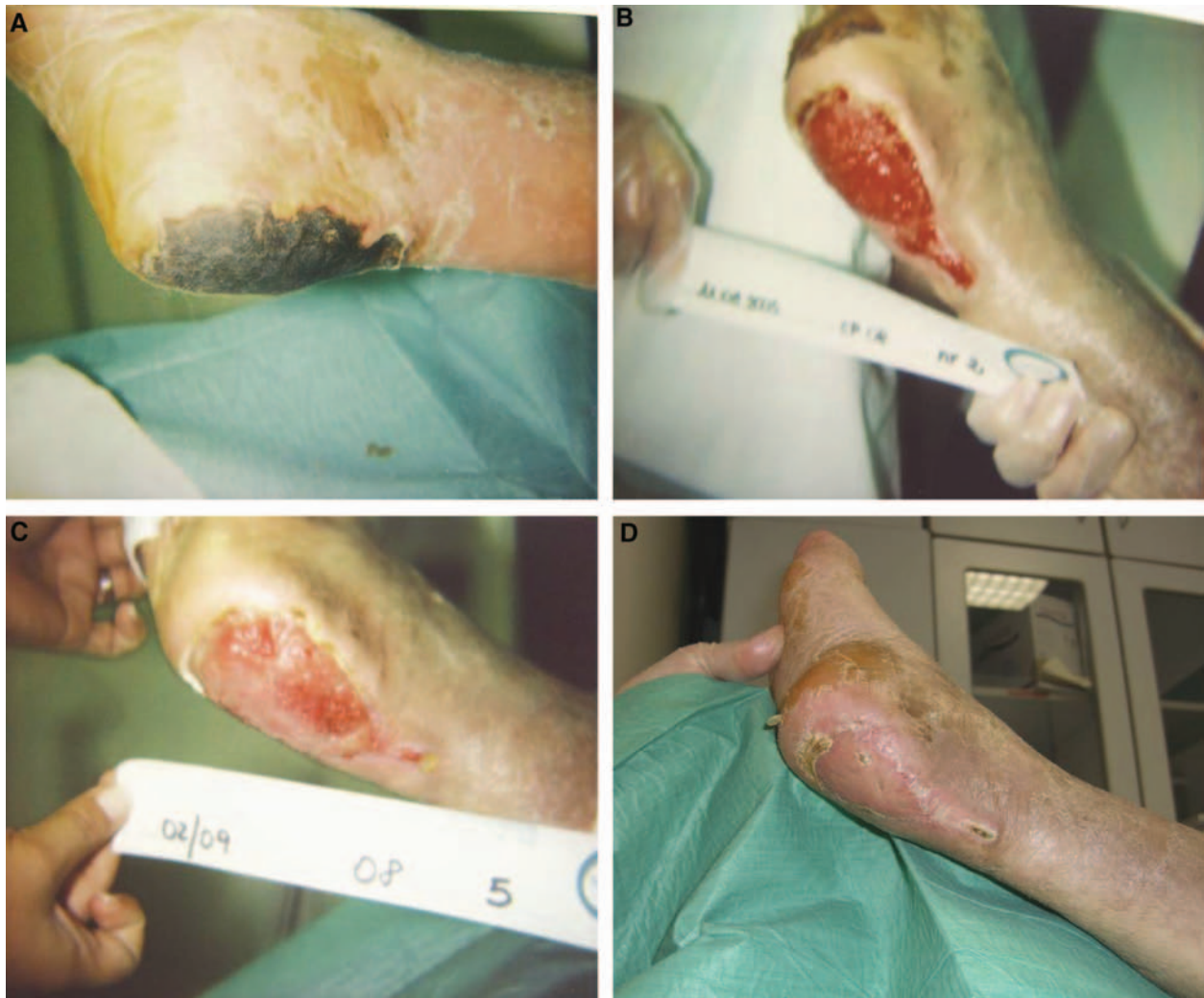**RESULTS**

Twenty-two patients fulfilled the inclusion and exclusion criteria, but only 18 were enrolled. Three out of the 4 patients not enrolled were unable to attend all the control visits because of the distance between their homes and the foot clinic. The remaining patient did not give informed consent. The patient demographics for both groups are presented in Table 1.

All of the patients in the study had lesions, which were a consequence of surgical debridement and included conservative minor amputations, necrosectomy, and drainage. These were allowed to close with secondary intent.

At baseline, there were no significant differences between the 2 groups in the number of minor amputations (9 in group A versus 8 in group B, not significant). This was also the case for the number of revascularizations in the 2 groups (8 in group A versus 8 in group B, not significant). No adverse events occurred in the patients in group A, but 1 patient in group B withdrew on account of topical dermatitis.

At the end of the study at follow-up, the frequency of minor amputations was significantly greater in group B compared with group A (see Figure 1). Healing times were significantly faster in group A patients compared with patients in group B, mean ± 1 SD (95% CI) (144.6 ± 39.2 [125.4-163.6] versus 212.3 ± 67.8 [178.6-246.9] days, P = .00361). In addition, the proportion of patients healed in 6 months



*Fig. 2 A case managed with Dermacyn. A) a wide necrotic area in the Achilles tendon region caused by the presence of ischemia and infection induced by trauma from shoes. B) The patient after revascularization, surgical debridement, and 2 weeks of treatment with Dermacyn-saturated dressings. Granulation tissue is present over 100% of the lesion and completely covers the exposed tendon. C) The lesion after another month of treatment with Dermacyn-saturated dressings. A reduction of 25% of the lesion area is noticeable in addition to reduction of the perilesional inflammation signs. This lesion was then suitable for grafting. D) The lesion 3 weeks after the grafting procedure. Complete epithelialization has occurred.*

was significantly higher in group A than in group B (87.5% vs 51.4%,  $P = .00827$ ).

The duration of antibiotic therapy was shorter in group A than in group B patients ( $74.7 \pm 32.1$  [59.1-90.3] vs  $129.6 \pm 54.4$  [98.2-159.9] days,  $P = .01373$ ). The incidence of reinfection was significantly less among patients in group A compared with group B (4 vs 9,  $P = .00154$ ). This was also the case for the incidence of surgical debridement procedures during follow-up (6 for group A vs 16 for group B,  $P = .00121$ ).

There were no differences in healing rates and times between patients who underwent successful revascularization and those who did not need it in both treatment groups.

## DISCUSSION

The aim of this study was to examine the use of DWC-soaked dressings plus our standard therapy against our previous treatment regime using a quasi-experimental (nonrandomized) study design. The

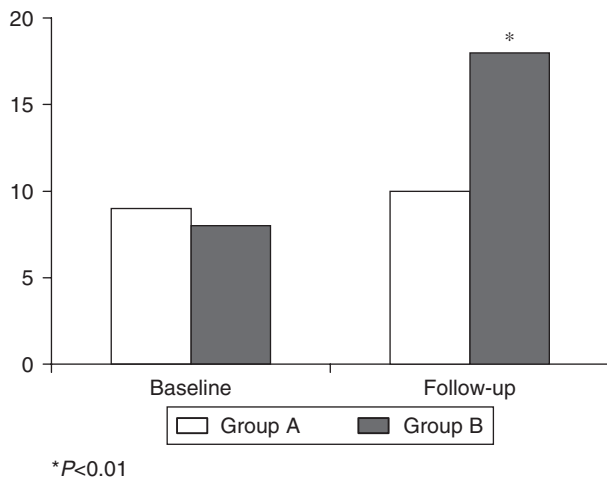


Fig. 3 The number of minor amputations in both groups at baseline and after follow-up. In the group managed with povidone-iodine dressings (group B), the number of minor amputations following debridement procedures significantly increased in contrast to the group treated with Dermacyn (group A).

only difference between the treatment regimes for the 2 groups was the method used for wound dressing.

The management of infected lesions of the diabetic foot is probably the most demanding task in this field and involves off-loading of the wounds, revascularization, and surgical debridement in addition to systemic antibiotic therapy.<sup>16</sup> Topical antiseptics are widely used in clinical practice to prevent recurrence of infection, especially in postsurgical lesions that are left to heal by secondary intent.<sup>17</sup> This study shows that the DWC-soaked dressings method was safer and more effective than our previously used standard treatment in the management of wide and deep lesions of diabetic feet that were secondary to surgical debridement or drainage.

DWC-soaked dressings use was associated with a shorter healing time and a higher proportion of patients who were healed in 6 months, both findings being statistically significant as presented in the previous section. There was concomitant reduction in the frequency of recurrent infection and in required additional surgical procedures during follow-up in this group. We consider the results from this study to be important because deep infection of the feet of patients with diabetes increases the risk of patients requiring partial or full amputation of the foot.<sup>18,19</sup>

Any treatment strategy to manage the diabetic foot is complex and should focus on reduction of infection. This may include aggressive surgical debridement to remove nonviable tissue, reduction of the

bacterial load with systemic antibiotics, revascularization if required, and local management of the lesion. A lesion may be wide and deep as a result of the debridement, therefore leaving it more exposed to reinfection. This is coupled with the fact that the immune response of a patient with diabetes may be impaired. The situation is further complicated by the complex anatomy of the foot, and infection can involve deeper structures such as joints and bones. The use of topical antiseptics could help reduce the bacterial load and the risk of recurrent infection.<sup>20</sup>

We postulate that the mechanism of action of DWC is related to the many different reactive species present in the SOS as a result of electrolysis. Their action is related to their ability to break bacterial cell walls and to inactivate the cytoplasmic enzymes of many strains of bacteria, which was reported from studies using electron microscopy.<sup>10,11</sup>

In preclinical studies, SOSs have been shown to have broad antimicrobial activity and healing properties.<sup>12</sup> Pilot studies in humans have been encouraging in various conditions.<sup>21</sup> The major problems with SOSs have been related to their toxicity in living tissues because of their pH, and their stability over time.<sup>22</sup> DWC has been shown to be safe in several tissues including dermis, mucosa, and peritoneum.<sup>23</sup> In contrast to other SOSs, it is stable over time and has a shelf life of greater than 1 year, which is important in clinical practice.

One of the most important observations from this study was the shorter duration of required systemic antibiotic therapy and the reduced number of debridement procedures, which were required by patients treated with DWC. The reduction in the number of required procedures in this group may be associated with the observed improved wound healing in group A (treated DWC dressings), though we did not test for the statistical validity of this observation.

We compared DWC-soaked dressings with those soaked using povidone iodine. Povidone iodine has been shown to be an effective antimicrobial agent for the treatment of various conditions and is routinely used for the management of chronic wounds.<sup>24,25</sup> The significantly faster healing time and shorter duration of required antibiotic therapy in patients treated with DWC indicates that this SOS has superior antimicrobial activity than povidone iodine, which includes bacterial strains such as vancomycin-resistant *enterococcus* and methicillin-resistant *Staphylococcus aureus*.<sup>11</sup> This observed effect may also be attributed to other events that contribute to the healing process such as stimulation of fibroblast proliferation or angiogenesis.<sup>12</sup>

The results from this small study show that DWC was more effective than povidone iodine in treating wide postsurgical infected wounds of the diabetic foot and promoting healing. However, there were no differences in safety between the 2 treatments.

### Limitations of This Study

One limitation of this study was its design, which was quasi-experimental, that is, nonrandomized. The sample sizes were also small. We consider the evidence to be good but at a level lower than evidence that influences evidence-based practice. We are cautious about the interpretations of these findings and urge the need for a randomized control trial. Such a trial is being undertaken in the authors' department to further examine the findings presented in this report.

### ACKNOWLEDGMENTS

We thank Dr Debbie Reynolds at Dianthus Medical Limited, London, for medical writing assistance.

### REFERENCES

1. Caputo GM, Cavanagh PR, Ulbrecht JS, Gibbons GW, Karchmer AW. Assessment and management of foot disease in patients with diabetes. *N Engl J Med* 1994;331:854-60.
2. Boulton AJ. Clinical presentation and management of diabetic neuropathy and foot ulceration. *Diabet Med* 1991;8:S52-7.
3. Levin ME. Preventing amputations in the patient with diabetes. *Diabetes Care* 1995;18:1383-94.
4. Schaper NC, Apelqvist J, Bakker K. The international consensus and practical guidelines on the management and prevention of the diabetic foot. *Curr Diab Rep* 2003;3:475-9.
5. Eneroth M, Apelqvist J, Stenstrom A. Clinical Characteristics and outcome in 223 diabetic patients with deep foot infections. *Foot Ankle Int* 1997;18:716-22.
6. Lipsky BA. The International Consensus Working Group on Diagnosing and Treating the Infected Diabetic Foot: a report from the international consensus on diagnosing and treating the infected diabetic foot [Review]. *Diabetes Metab Res Rev* 2004;20(Suppl 1):S68-77.
7. Eckman MH, Greenfield S, Mackey WC, Wong JB, Kaplan S, Sullivan L, et al. Foot infections in diabetic patients: decision and cost-effective analyses. *JAMA* 1995;273:712-20.
8. Flynn J. Povidone-iodine as a topical antiseptic for treating and preventing wound infection: a literature review. *Br J Commun Nurs* 2003;8:S36-42.
9. Daroczy J. Quality control in chronic wound management: the role of local povidone-iodine (Betadine) therapy. *Dermatology* 2006;212(Suppl 1):82-7.
10. Tanaka H, Hirakata Y, Kaku M, Yoshida R, Takemura H, Mizukane R, et al. Antimicrobial activity of superoxidized water. *J Hosp Infect* 1996;34:43-9.
11. Venkitanarayanan KS, Ezeike GO, Hung YC, Doyle MP. Efficacy of electrolyzed oxidizing water for inactivating *Escherichia coli* O157:H7, *Salmonella enteritidis*, and *Listeria monocytogenes*. *Appl Environ Microbiol* 1999;65:4276-9.
12. Yahagi N, Kono M, Kithara M, Ohmura A, Sumita O, Hashimoto T, et al. Effect of electrolyzed water on wound healing. *Artif Organs* 2000;24:984-7.
13. Report of the expert committee on the diagnosis and classification of diabetes mellitus. *Diabetes Care* 1997;20:1183-97.
14. Lavery LA, Armstrong DG, Harkless LB. Classification of diabetic foot wounds. *J Foot Ankle Surg* 1996;35:528-31.
15. Katz IA, Harlan A, Miranda-Palma B, Prieto-Sanchez L, Armstrong DG, Bowker JH, et al. A randomized trial of two irremovable off-loading devices in the management of plantar neuropathic foot ulcers. *Diabetes Care* 2005;28:555-9.
16. Joshi N, Caputo GM, Weitekamp MR, Karchmer AW. Infections in patients with diabetes mellitus. *N Engl J Med* 1999;341:1906-12.
17. Lipsky BA, Pecoraro RE, Wheat LJ. The diabetic foot: soft tissue and bone infection. *Infect Dis Clin North Am* 1990;4:409-32.
18. LeFrock JL, Joseph WS. Bone and soft tissue infections of the lower extremity in diabetics. *Clin Podiatr Med Surg* 1995;12:87-103.
19. Waugh NR. Amputations in diabetic patients: a review of rates, relative risks and resource use. *Commun Med* 1988;10:279-88.
20. Lipsky BA, Berendt AR, Deery HG, Embil JM, Joseph WS, Karchmer AW, et al. Infectious Diseases Society of America. Diagnosis and treatment of diabetic foot infections. *Clin Infect Dis* 2004;39:885-910.
21. Landa-Solis C, Gonzalez-Espinosa D, Guzman-Soriano B, Snyder M, Reyes-Teran G, Torres K, et al. Microcyn™ a novel super-oxidized water with neutral pH and disinfectant activity. *J Hosp Infect* 2005;61:291-9.
22. Sampson MN, Muir AV. Not all the super-oxidized waters are the same. *J Hosp Infect* 2002;52:228-9.
23. Ohno H, Higashidate M, Yokosuka T. Mediastinal irrigation with superoxidized water after open-heart surgery: the safety and pitfalls of cardiovascular surgical application. *Surg Today* 2000;30:1055-6.
24. Lawrence JC. A povidone-iodine medicated dressing [Review]. *J Wound Care* 1998;7:332-6.
25. Selvaggi G, Monstrey S, Van Landuyt K, Hamdi M, Blondeel P. The role of iodine in antisepsis and wound management: a reappraisal. *Acta Chir Belg* 2003;103:241-7.