

See discussions, stats, and author profiles for this publication at: <https://www.researchgate.net/publication/303289568>

Adjunctive Debridement with Hypochlorous Acid for Healing Complex Wounds in Children

Conference Paper · April 2016

CITATIONS

0

READS

47

1 author:



Ferne Elsass

Children's Hospital of the King's Daughters

3 PUBLICATIONS 0 CITATIONS

SEE PROFILE

Some of the authors of this publication are also working on these related projects:



currently working on pressure injury prevention in pediatrics [View project](#)

ADJUNCTIVE DEBRIDEMENT WITH HYPOCHLOROUS ACID LEADS TO A HEALING TRAJECTORY OF COMPLEX WOUNDS IN CHILDREN

Ferne T. Elsass, MSN, RN, CPN, CWON; Clinical Practice and Education Specialist of Wound and Ostomy, Children's Hospital of The King's Daughters, Norfolk, VA 23507

Introduction: Complex wounds such as deep pressure ulcers, epidermolysis bullosa, sternal wounds following cardiac surgery, and wounds in compromised patients require multiple modalities to advance each wound to a healing trajectory.

Problem: Surgical correction of the wound with techniques such as pedicled or free flaps are often not possible because of the overall condition of the patient. Surgical debridement may be contraindicated in the most severely ill patients.

Methods: Because the eschar presenting on most of these wounds is dry, a Leptospermum honey* has been the mainstay of our nonsurgical debridement. Recently, we have added hypochlorous acid** irrigation and soaks to the wounds. We have used this treatment in a series of 12 patients with a total of 16 wounds.

Results: The hypochlorous acid treatment not only served as an adjunct to debridement, but accelerated the wounds in leading to a healing trajectory. Once debridement was complete, continued soaks with hypochlorous acid led to rapid and complete healing of the wounds. In patients with the major wounds, the hypochlorous acid was also used to cleanse around tracheostomy sites and gastrointestinal tube egress sites with successful healing of any denuded areas. Four illustrative cases from the series are depicted.

Case 1: A 7 mo. old female with an atrioventricular canal defect and post-op pulmonary hypertension developed an occipital pressure ulcer secondary to positioning of a blanket roll (Fig.1a). Eschar was debrided with a honey hydrocolloid dressing (Fig.1b). Treatment was begun with hypochlorous acid soaks for 5 min. followed by honey dressings every other day. The ulcer assumed a healing trajectory on the hypochlorous acid / honey regimen (Fig. 1c), and was completely healed after 5 weeks of treatment (Fig. 1d).

Case 2: The same patient as in Case 1 developed a left gluteal pressure ulcer which was initially debrided with honey dressings (Fig.2a). Treatment continued with hypochlorous acid soaks followed by honey dressings changed every other day showed a healing trajectory (Fig.2b) and complete healing at 5 weeks.

Case 3: A 2 yr. old female was seen 3 days after a lawn mower accident involving the left arm. Following debridement the wound was treated with hypochlorous acid soaks for 5-10 minutes followed by application of negative pressure wound therapy (NPWT) (Fig.3a). While the wound steadily improved, bone exposure required a muscle flap (Fig.3b). Hypochlorous acid and NPWT allowed the muscle flap to close most of the defect (Fig.3c). The patient was discharged on hypochlorous acid soaks and NPWT to await final skin-grafting at 6 weeks. Following initial injury (Fig.3d).

Case 4: A 15 yr. old female with severe pneumonia and a respiratory arrest requiring a tracheostomy developed an occipital pressure ulcer (Fig. 4a). The wound was debrided sharply and with Leptospermum honey (Fig.4b). Treatment was changed to hypochlorous acid soaks and honey dressings every other day and achieved a healing trajectory (Fig. 4c). The ulcer continued healing (Fig.4d), and was totally closed at 12 weeks without requiring any surgery.

Conclusions: Hypochlorous acid proved to be adjunctive to debridement in ten patients with 14 wounds. Continued use following debridement led to a healing trajectory in these complex wounds in children.

References

1. Couch KS, Miller C, Cnossen LA, Richey KJ, Guinn SJ: Non-cytotoxic wound bed preparation: Vashe Hypochlorous acid wound cleansing solution. Wound Source White Paper, Sept 2015.
2. Miller C, Mouhlas A: Significant cost savings realized by changing debridement protocol. Ostomy Wound Manage 2014; 60(9): 8-9.



Fig.1a

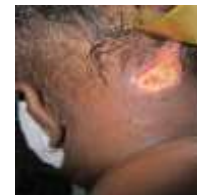

Fig.1b

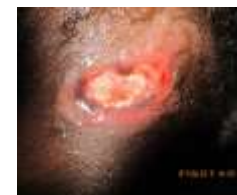

Fig.1c

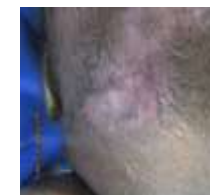

Fig.1d

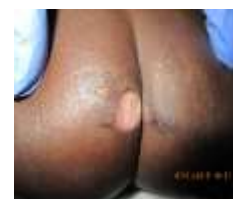

Fig.2a

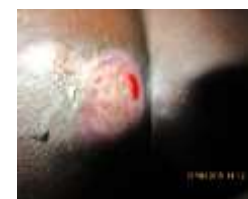

Fig. 2b

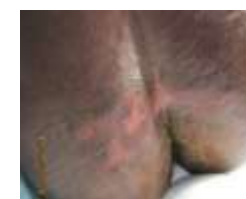

Fig.2c

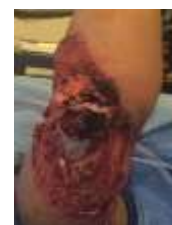

Fig.3a

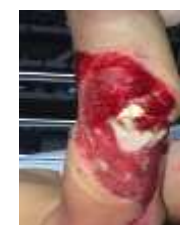

Fig.3b

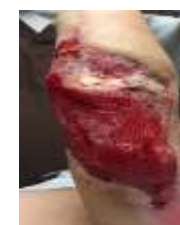

Fig.3c



Fig.3d



Fig.4a

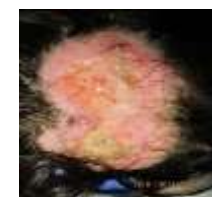

Fig.4b

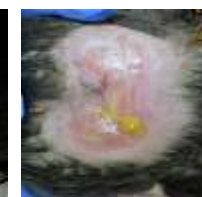


Fig.4c

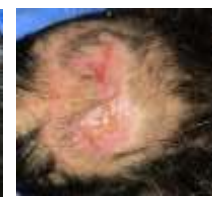

Fig.4d

*Medihoney, Dermasciences, Princeton, NJ
**Vashe Wound Solution, SteadMed Medical LLC
Fort Worth, TX